

**12****AUTOPSY REPORT**

No.

2010-02964

LOPEZ, PETER

I performed an autopsy on the body of  
at the DEPARTMENT OF CORONER

Los Angeles, Californiaon MAY 1, 2010 @ 0830 HOURS

(Date)

(Time)

From the anatomic findings and pertinent history I ascribe the death to:

(A) GUNSHOT WOUND OF HEAD

DUE TO, OR AS A CONSEQUENCE OF

(B)

DUE TO, OR AS A CONSEQUENCE OF

(C)

DUE TO, OR AS A CONSEQUENCE OF

(D)

OTHER CONDITIONS CONTRIBUTING BUT NOT RELATED TO THE IMMEDIATE CAUSE OF DEATH:

**Anatomical Summary:**

- I. Gunshot wound of head.
  - A. Contact gunshot wound of head.
  - B. Direction: Right to left, front to back, and downward.
  - C. Path: Skull, brain.
  - D. Exit: None.
  - E. Projectile: Medium caliber bullet recovered in brain.
- II. Autopsy unremarkable.



**12****AUTOPSY REPORT**

No.

2010-02964

LOPEZ, PETER

2

Page \_\_\_\_\_

**SUMMARY OF EVENTS:**

The decedent is a 60-year-old Hispanic male who was found down at his residence with an apparent single gunshot wound of the head. A note was present.

**EVIDENCE OF INJURY:**Gunshot wound of head:

Examination of the head reveals a contact-type gunshot wound to the right temporal scalp, located 2-1/4 inches from the top of the head and 4-1/2 inches right of the midline. The stellate wound measures 3/4 inch in diameter with skin tears present at the 3, 6 and 9 o'clock positions. A thin red abrasion rim is also noted extending from the 3 to 9 o'clock position. Dark gray material consistent with sooting is noted within the wound. No stippling is present. The direction is right to left, front to back, and downward. After perforating the skin, the projectile impacts and fractures the right temporal bone causing numerous fragments to be pushed into the brain matter. There is extensive tissue disruption and hemorrhage of the right frontal and temporal lobes of the brain. The hemorrhagic wound track then crosses the midline through the basal ganglia and exits inferiorly, perforating the left lobe of the cerebellum. The projectile recovered at 0940 hours consists of a deformed medium caliber bullet with copper jacket and open base, as well as a separate metal fragment appearing to be a lead fragment. Both are recovered from the base of the cerebellum. The bullet and fragment are placed into an evidence envelope and placed into the evidence safe. Associated with this gunshot wound is extensive fracturing of the frontal, parietal and occipital bones, as well as the base of the skull including the anterior, middle and posterior cranial fossae. Subdural hemorrhage is present in both hemispheres consisting of 5 cc of blood present in the right and left cerebral hemispheres, as well as diffuse subarachnoid hemorrhage. This is an instantly fatal wound.



**12****AUTOPSY REPORT**

No.

2010-02964

LOPEZ, PETER

Page 3**EXTERNAL EXAMINATION:**

The body is identified by toe tags and is that of an unembalmed, refrigerated adult Hispanic male who appears about the reported age of 60 years. The body weighs 174 pounds, measures 71 inches, and is well-built, muscular and well-nourished.

The skin is free of abrasions, bruises, lacerations, scars and burns. Debris is noted to the back and legs in the form of leaves, twigs, grass and some rocks. Tattoos are absent. Rigor mortis is present. Livor mortis is fixed and posterior.

The head is normocephalic and covered by brown hair. There is no balding, and the hair can be described as short and wavy. Mustache and beard are absent. Examination of the eyes reveals irides that appear to be brown in color and sclerae that are white. There are no petechial hemorrhages of the conjunctivae of the lids or the sclerae. The oronasal passages are unobstructed. Upper and lower teeth are present. The neck is unremarkable. There is no chest deformity. There is no increased anterior-posterior diameter. The abdomen is flat. The genitalia are those of an adult male. The penis appears uncircumcised. The external genitalia are without trauma or lesions. The extremities show no edema, joint deformity, abnormal mobility or needle tracks.

**EVIDENCE OF THERAPEUTIC INTERVENTION:**

None. There has not been postmortem intervention for organ procurement.

**CLOTHING:**

The body was not clothed, and I did not see the clothing.



**12****AUTOPSY REPORT**

No.

2010-02964

LOPEZ, PETER

Page 4**INITIAL INCISION:**

The body cavities are entered through the standard coronal incision and the standard Y-shaped incision. No foreign material is present in the mouth, upper airway and trachea.

**NECK:**

The neck organs are removed en bloc with the tongue. No lesions are present, nor is trauma of the gingiva, lips or oral mucosa demonstrated. There is no edema of the larynx. Both hyoid bone and larynx are intact and without fractures. No hemorrhage is present in the adjacent throat organs, investing fascia, strap muscles, thyroid or visceral fascia. There are no prevertebral fascial hemorrhages. The tongue when sectioned shows no trauma.

**CHEST/ABDOMINAL CAVITY:**

Both pleural cavities contain no fluid or adhesions. No tension pneumothorax is demonstrated. The parietal pleurae are intact. The lungs are voluminous. Soft tissues of the thoracic and abdominal walls are well-preserved. The organs of the abdominal cavity have a normal arrangement, and none are absent. There is no fluid collection. The peritoneal cavity is without evidence of peritonitis. There are no adhesions.

**SYSTEMIC AND ORGAN REVIEW**

The following observations are limited to findings other than injuries, if described above.

**MUSCULOSKELETAL SYSTEM:**

No abnormalities of the bony framework or muscles are present.



**12****AUTOPSY REPORT**

No.

2010-02964

LOPEZ, PETER

Page 5**CARDIOVASCULAR SYSTEM:**

The aorta is elastic and of even caliber throughout, with vessels distributed normally from it. The apex of the thoracic aorta shows moderate atherosclerosis. The remainder of the aorta shows minimal lipid streaking. There is no tortuosity or widening of the thoracic segment. There is no dilation of the lower abdominal segment. No aneurysm is present. The major branches of the aorta show no abnormality.

Within the pericardial sac, there is a minimal amount of serous fluid. The heart weighs 360 grams and has a normal configuration. The right ventricle is 0.5 cm thick, and the left ventricle is 1.4 cm thick. The chambers are normally developed and are without mural thrombosis. The valves are thin, leafy and competent. The circumferences of the valve rings are: Tricuspid valve 11.8 cm, pulmonic valve 6.2 cm, mitral valve 10.4 cm, and aortic valve 6.4 cm. There is no endocardial discoloration. There are no lesions of the myocardium. There is no abnormality of the apices of the papillary musculature. There are no defects of the septum. The great vessels enter and leave in a normal fashion. The coronary ostia are widely patent. There is no coronary atherosclerosis of the major coronary arteries. No focal endocardial, valvular or myocardial lesions are seen. The blood within the heart and large blood vessels is liquid.

**RESPIRATORY SYSTEM:**

No secretions are found in the lower bronchial passages. The mucosa is intact and pale. The lungs are crepitant, and there is dependent congestion. The left lung weighs 390 grams. The right lung weighs 450 grams. The visceral pleurae are smooth and intact. The parenchyma is mildly congested. The pulmonary vasculature is without thromboembolism.



**12****AUTOPSY REPORT**

No.

2010-02964

LOPEZ, PETER

6

Page \_\_\_\_\_

**GASTROINTESTINAL SYSTEM:**

The esophagus is intact throughout. The stomach is not distended by gas. It contains no food. The mucosa is unremarkable. No tablets or capsules are identified. The small intestine and colon are opened along the anti-mesenteric border, showing diverticulosis of the distal descending colon. The appendix is present. The pancreas occupies a normal position. There is no trauma. The parenchyma is lobular and firm. The pancreatic ducts are not ectatic, and there is no parenchymal calcification.

**HEPATOBIILIARY SYSTEM:**

The liver weighs 1220 grams, is of average size, and is red-brown. The capsule is intact, and the consistency of the parenchyma is firm. The cut surface is smooth. There is a normal lobular arrangement. The gallbladder is present. The wall is thin and pliable. It contains less than 5 cc of bile and no calculi.

**URINARY SYSTEM:**

The left kidney weighs 160 grams. The right kidney weighs 150 grams. The kidneys are normally situated, and the capsules strip easily revealing a surface that is smooth. The cortico-medullary demarcation is preserved. The pyramids are not remarkable. The peripelvic fat is not increased. The ureters are without dilation or obstruction and pursue their normal course. The urinary bladder is unremarkable. It contains 160 cc of clear amber urine. The urine is tested by the dipstick method, and the results are negative for glucose.

**GENITAL SYSTEM (MALE):**

The prostate is without enlargement or nodularity. Both testes are in the scrotum and are unremarkable and without trauma.



**12****AUTOPSY REPORT**

No.

2010-02964

LOPEZ, PETER

Page 7

## HEMOLYMPHATIC SYSTEM:

The spleen weighs 120 grams and is of average size. An accessory spleen is noted attached to the epiploic fat of the transverse colon at the splenic flexure. There is no increased follicular pattern. The bone is not remarkable. The bone marrow of the ribs is red and moist.

## ENDOCRINE SYSTEM:

The thyroid is unremarkable. The parathyroid glands are not identified. The adrenals are intact without necrosis or hemorrhage. The pituitary gland is not examined due to extensive injury of the sella turcica caused by the gunshot wound of the head.

## SPECIAL SENSES:

The eyes, middle and inner ears are not dissected.

## HEAD AND CENTRAL NERVOUS SYSTEM:

There is extensive subcutaneous and subgaleal hemorrhage of the scalp. The hemorrhage extends into both right and left temporal muscles. The external periosteum and dura mater are stripped showing numerous radiating fractures of the calvarium and base of the skull. Subdural and subarachnoid hemorrhages are present as previously described. Please see "Evidence of Injury" for description of the brain.

## SPINAL CORD:

The entire cord is not dissected.

## HISTOLOGIC SECTIONS:

Representative sections from various organs are preserved in one storage jar in 10% formalin.



**12****AUTOPSY REPORT**

No.

2010-02964

LOPEZ, PETER

Page 8

## TOXICOLOGY:

Bile, blood, liver tissue, urine, and vitreous humor have been submitted to the laboratory. A comprehensive screen was requested.

## PHOTOGRAPHY:

Photographs have been taken prior to the course of the autopsy.

## RADIOLOGY:

The body is fluoroscoped, and x-rays are taken of the head. Foreign body consistent with a bullet is present.

## WITNESSES:

None.

## DIAGRAMS USED:

Diagram Forms 20, 22, 28 and 29 were used during the performance of the autopsy. The diagrams are not intended to be facsimiles.

## OPINION:

The cause of death of this 60-year-old male is due to a single self-inflicted gunshot wound of the head. The manner of death is suicide.

  
JUAN M. CARRILLO, M.D.  
DEPUTY MEDICAL EXAMINER

DATE

5/5/2010

JMC:am/cv:c/f  
T-05/04/10



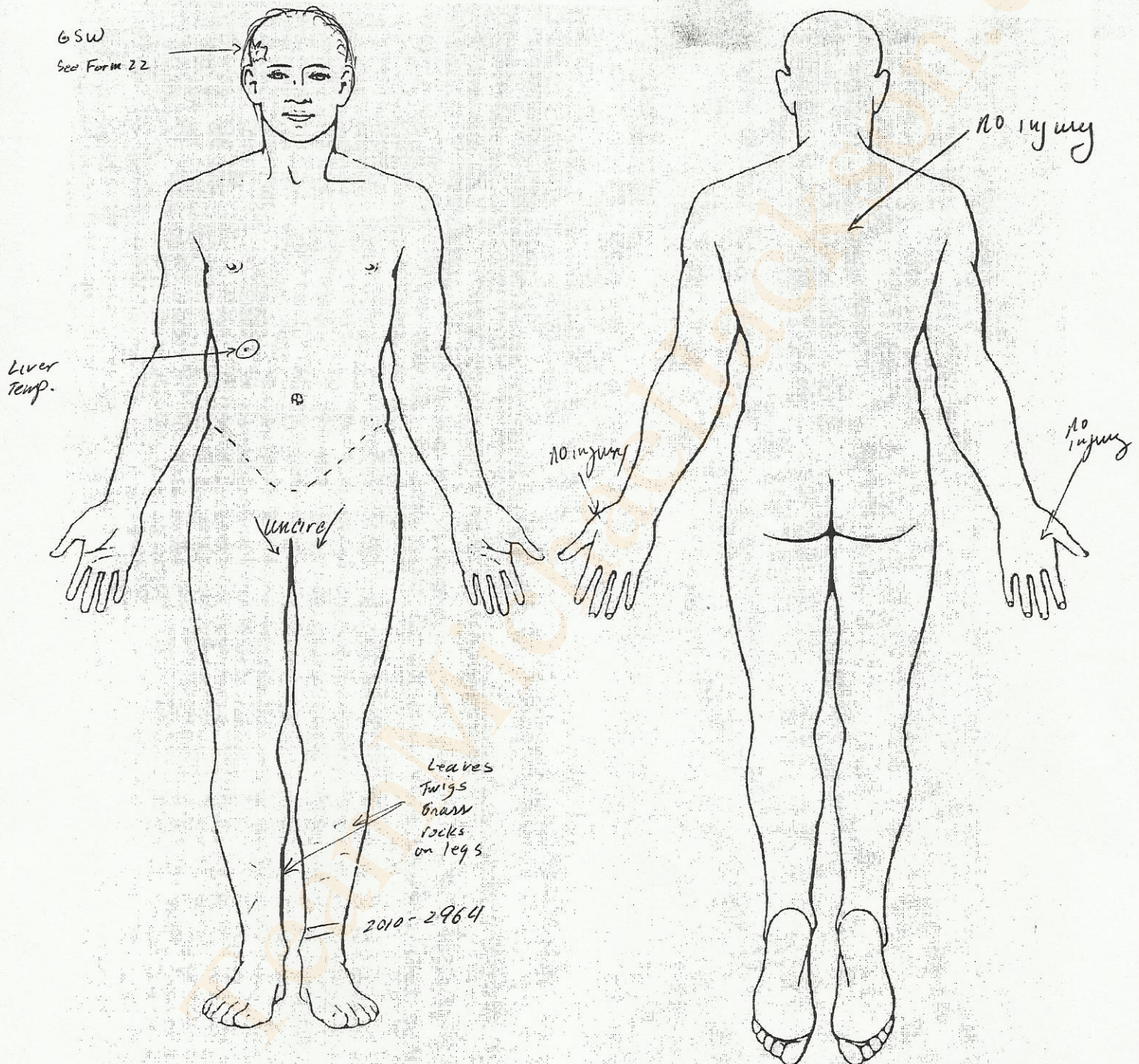
**20**

2010-02964

LOPEZ, PETER

SUI

LAPD WEST VALLEY 204



Date

*[Signature]* 5/1/2010 M.D.  
Deputy Medical Examiner



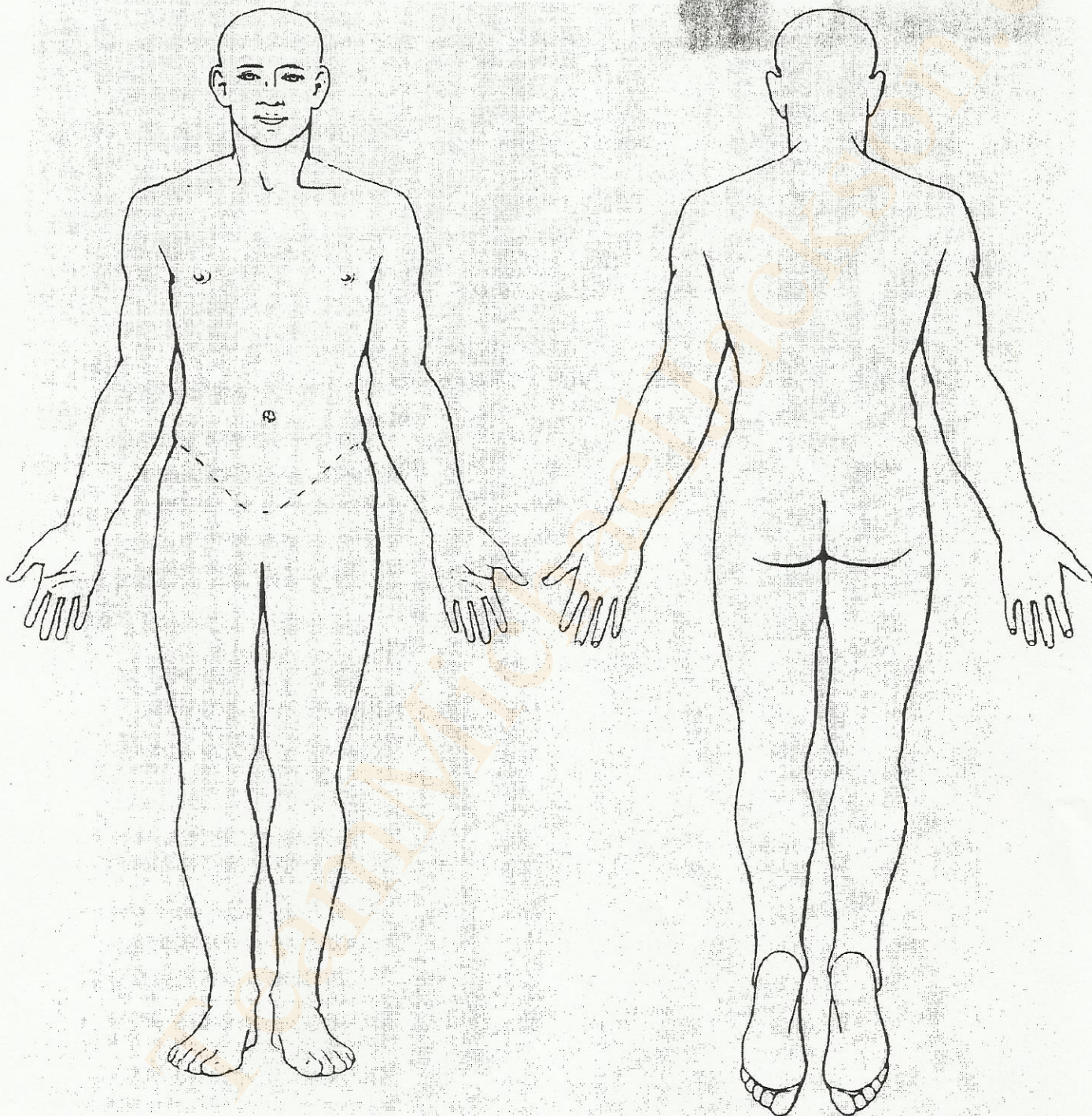
**20**

2010-02964

LOPEZ, PETER

SUI

LAPD WEST VALLEY 204



Date

*[Signature]* 5/1/2010 M.D.  
Deputy Medical Examiner




21

2010-02964


LOPEZ, PETER

SUI

LAPD WEST VALLEY 204



Rt



Lt

\_\_\_\_\_  
Deputy Medical Examiner M.D.



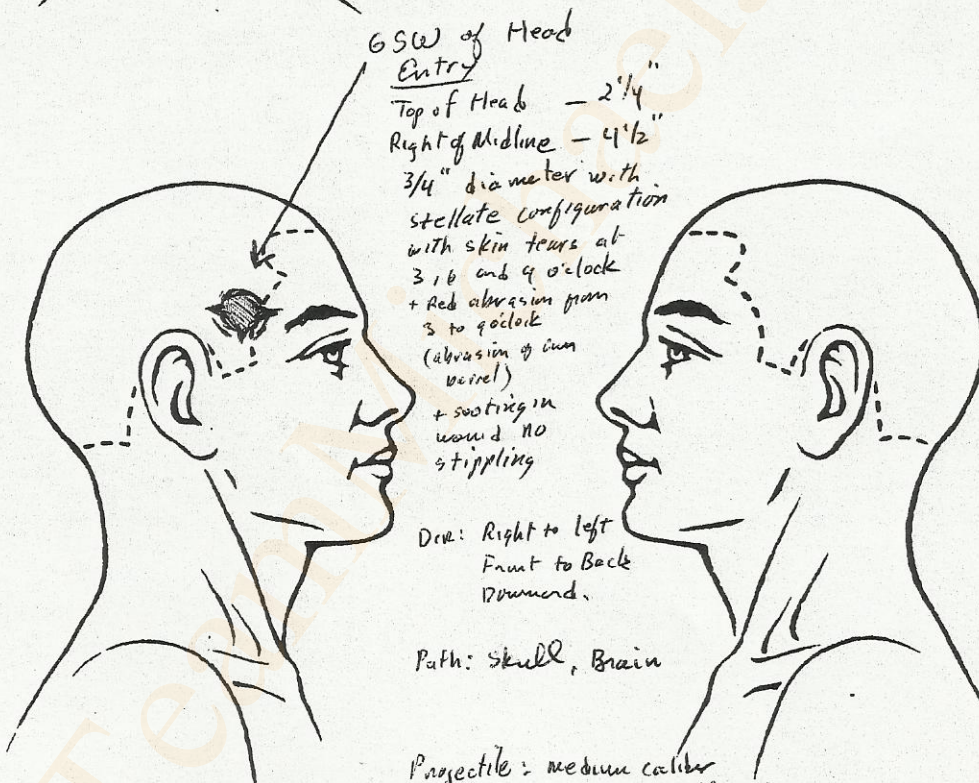
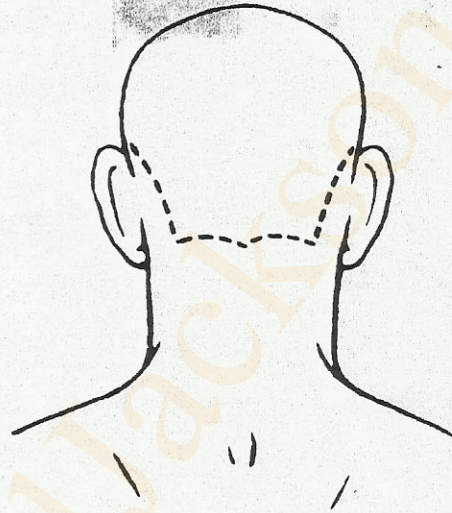
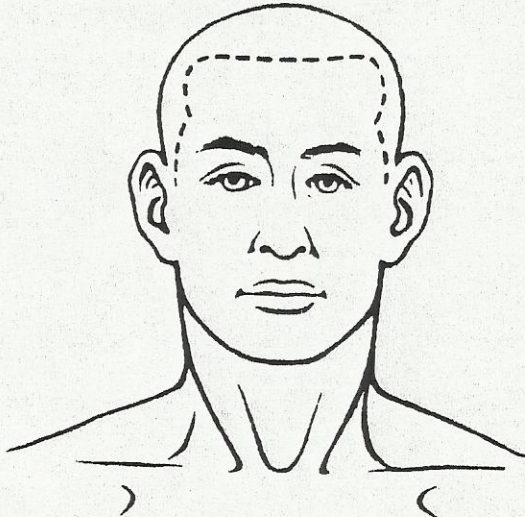
22

2010-02964

LOPEZ, PETER

SUI

LAPD WEST VALLEY 204



GSW of Head

Entry

Top of Head - 2 1/4"

Right of Midline - 4 1/2"

3/4" diameter with  
stellate configuration  
with skin tears at  
3, 6 and 9 o'clock  
+ Red abrasion from  
3 to 9 o'clock  
(abrasion of skin  
vein)+ soot in  
wound no  
stipplingDir: Right to left  
Front to Back  
Downward.

Path: Skull, Brain

Projectile: medium caliber  
deformed bullet  
with copper jacket  
open base rec @  
9:40 " base of  
left cerebellar lobe.

Date

Deputy Medical Examiner

M.D.



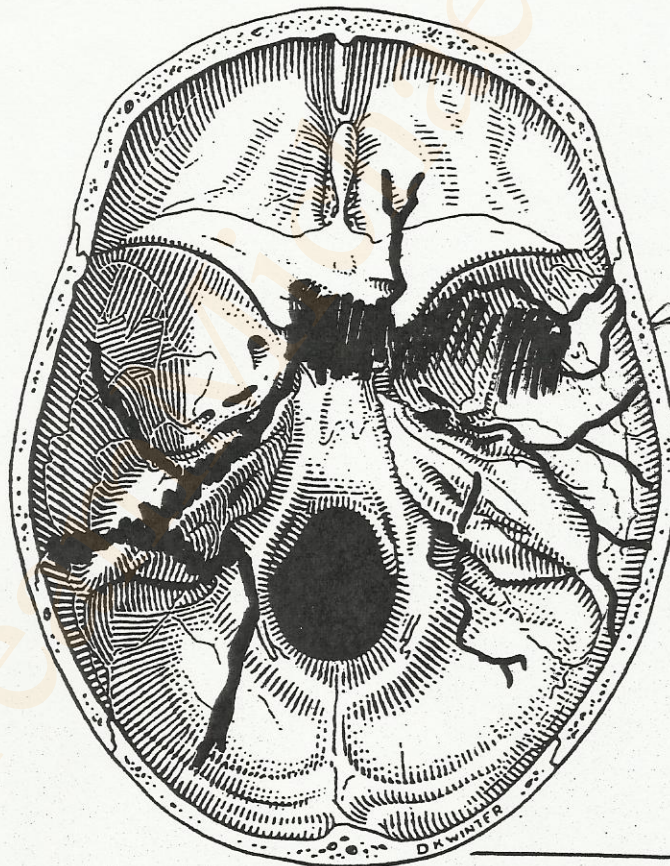
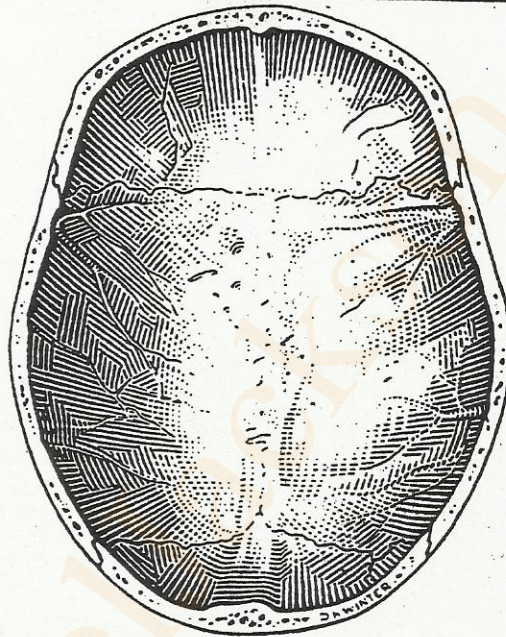
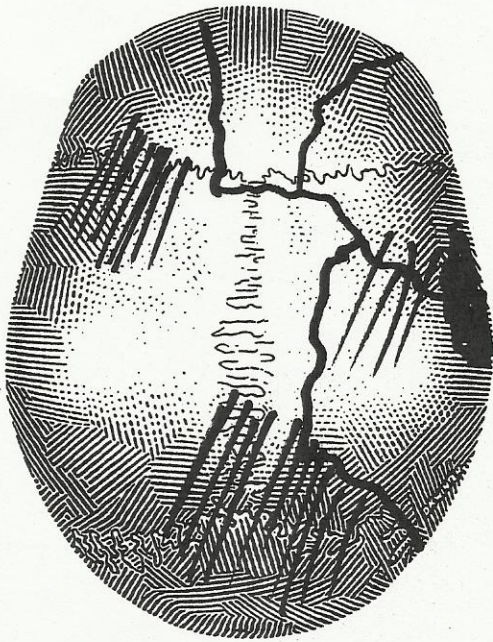
28

2010-02964

LOPEZ, PETER

SUI

LAPD WEST VALLEY 204

*multiple  
Fractures*

5/1/2010

M.D.

Deputy Medical Examiner



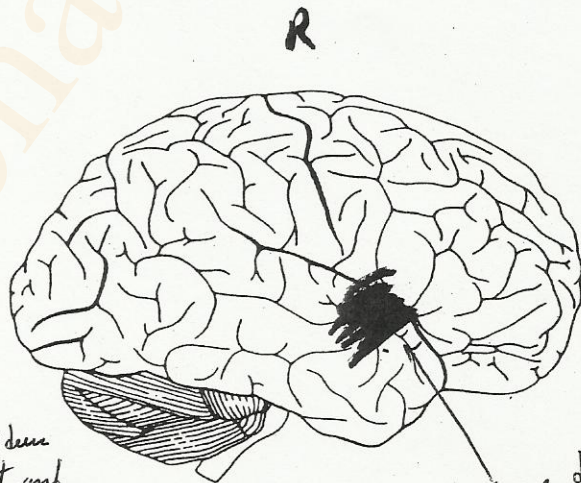
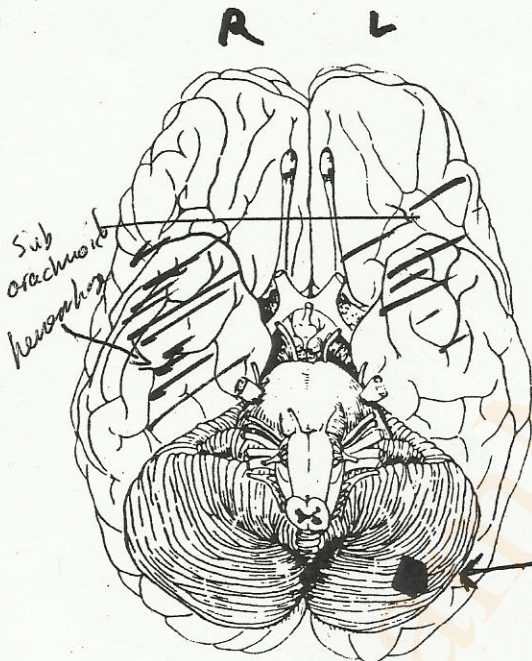
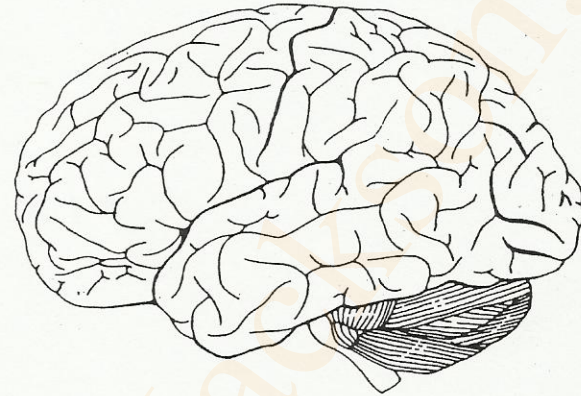
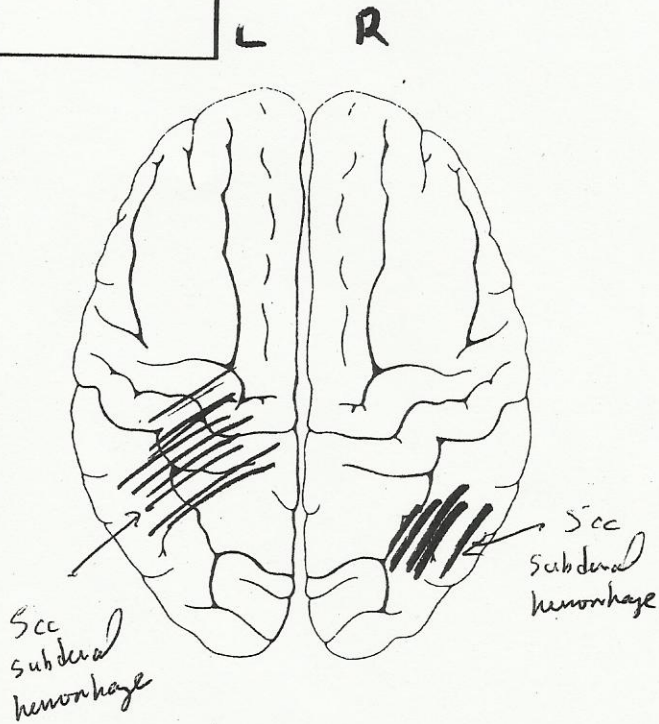
29

2010-02964

LOPEZ, PETER

SUI

LAPD WEST VALLEY 204



deformed .38 S&W  
Caliber bullet and  
metal fragment recovered  
@ 9:40am. placed into  
evidence envelope



*[Signature]*

5/1/2010

M.D.

Deputy Medical Examiner



**15**AUTOPSY CLASS: ☒ A ☐ B ☐ C ☐ Examination Only D☐ FAMILY OBJECTION TO AUTOPSYDate: 5/1/2010 Time: 8:30 Dr. Call  
(Print)FINAL ON: 5/1/2010 By: Call  
(Print)APPROXIMATE  
INTERVAL  
BETWEEN  
ONSET  
AND  
DEATH

2010-02964

LOPEZ, PETER

301

LAFD WEST VALLEY

204

DEATH WAS CAUSED BY: (Enter only one cause per line for A, B, C, and D)

## IMMEDIATE CAUSE:

(A) Gunshot Wound of Head

DUE TO, OR AS A CONSEQUENCE OF:

(B)

DUE TO, OR AS A CONSEQUENCE OF:

(C)

DUE TO, OR AS A CONSEQUENCE OF:

(D)

OTHER CONDITIONS CONTRIBUTING BUT NOT RELATED TO THE IMMEDIATE CAUSE OF DEATH:

☐ NATURAL ☒ SUICIDE ☐ HOMICIDE☐ ACCIDENT ☐ COULD NOT BE DETERMINEDIf other than natural causes,  
HOW DID INJURY OCCUR?shot self with gunWAS OPERATION PERFORMED FOR ANY CONDITION STATED ABOVE: ☐ YES ☒ NO

TYPE OF SURGERY: \_\_\_\_\_ DATE: \_\_\_\_\_

☐ ORGAN PROCUREMENT ☒ TECHNICIAN: Lopez, PaulPREGNANCY IN LAST YEAR ☐ YES ☐ NO ☐ UNK ☐ NOT APPLICABLE☐ WITNESS TO AUTOPSY ☐ EVIDENCE RECOVERED AT AUTOPSY  
Item Description:60 y.o. hispanic male found with  
GSW of head at residence Note present.request full tox by family.

RESIDENT

DME

Age: \_\_\_\_\_ Gender: Male / Female

## PRIOR EXAMINATION REVIEW BY DME

☒ BODY TAG ☐ CLOTHING  
☒ X-RAY (No. 2) ☒ FLUORO  
☐ SPECIAL PROCESSING TAG ☐ MED. RECORDS  
☐ AT SCENE PHOTOS (No. \_\_\_\_\_)

## CASE CIRCUMSTANCES

☐ EMBALMED  
☐ DECOMPOSED  
☐ >24 HRS IN HOSPITAL  
☐ OTHER: \_\_\_\_\_ (Reason)

## TYPING SPECIMEN

TYPING SPECIMEN TAKEN BY: \_\_\_\_\_

SOURCE: \_\_\_\_\_

## TOXICOLOGY SPECIMEN

COLLECTED BY: Call☒ HEART BLOOD ☐ STOMACH CONTENTS  
☒ FEMORAL BLOOD ☒ VITREOUSTECHNIQUE: ext.☐ \_\_\_\_\_ BLOOD ☐ SPLEEN  
☐ \_\_\_\_\_ BLOOD ☐ KIDNEY☒ BILE☒ LIVER☐ URINE

URINE GLUCOSE DIPSTICK RESULT: 4+ 3+ 2+ 1+ 0

TOX SPECIMEN RECONCILIATION BY: V

## HISTOLOGY

☒ Regular (No. 1) ☐ Oversize (No. \_\_\_\_\_)Histopath Cut: ☐ Autopsy ☐ Lab

## TOXICOLOGY REQUESTS

FORM 3A: ☐ YES ☐ NO☐ NO TOXICOLOGY REQUESTEDSCREEN ☒ C ☐ H ☐ T ☐ S ☐ D☐ ALCOHOL ONLY☐ CARBON MONOXIDE☐ OTHER (Specify drug and tissue)

## REQUESTED MATERIAL ON PENDING CASES

☐ POLICE REPORT ☐ MED HISTORY  
☐ TOX FOR COD ☐ HISTOLOGY  
☐ TOX FOR R/O ☐ INVESTIGATIONS  
☐ MICROBIOLOGY ☐ EYE PATH. CONS.  
☐ RADIOLOGY CONS.  
☐ CONSULT ON: \_\_\_\_\_  
☐ BRAIN SUBMITTED  
☐ NEURO CONSULT ☐ DME TO CUT  
☐ CRIMINALISTICS  
☐ GSR ☐ SEXUAL ASSAULT ☐ OTHER



**16**

10-02864

LOPEZ, PETER

SUI

LAPD WEST VALLEY 204

**EXTERNAL EXAM**

Sex  
Race  
Age  
Height  
Weight  
Hair  
Eyes  
Sclera  
Teeth  
Mouth  
Tongue  
Nose  
Chest  
Breasts  
Abdomen  
Scar  
Genitals  
Edema  
Skin  
Decubitus

**HEART Wt.** 360

Pericardium RV 0.5  
Hypertrophy T-11.8  
Dilation P-6.2 LV 1.4  
Muscle M-10.4  
Valves A-6.4  
Septum 1.2

Coronaries

**AORTA** + atherosclerosis, moderate to arch of aorta

**VESSELS****LUNGS Wt.**

R 1150  
L 390

Adhesions

Fluid

Atelectasis

Oedema

Congestion

Consolidation

Bronchi

Nodes

**PHARYNX** clay**TRACHEA****THYROID****THYMUS****LARYNX****HYOID** no Fractures**ABDOMINAL WALL FAT****PERITONEUM**

Fluid

Adhesions

**LIVER Wt.** 1220

Capsule

Lobules

Fibros

G B

Calculus

Bile ducts

**SPLEEN Wt.** 120

Color + accessory spleen on

Consistency + transverse colon

Capsule at splenic flexure

Malpiment

**PANCREAS** - accessory spleen**ADRENALS** - 0.5 cm dia**KIDNEYS Wt.**

R 150

L 160

Capsule

Cortex

Vessels

Pelvis

Ureters

**BLADDER** 160 cc chamber**GENITALIA** urine. negative for glucose

Prostate

Testes

Uterus

Tubes

Ovaries

**ESOPHAGUS****STOMACH**Contents ☒**DUOD. & SM. INT.****APPENDIX** ☒**LARGE INT.****ABDOM. NODES****SKELETON**

Spine

Marrow

Rib Cage

Long bones

Pelvis

**SCALP****CALVARIUM****BRAIN Wt.** 1480

Dura + Subdural hemorrhage

Fluid + Subarachnoid

Ventricles hemorrhage

Vessels

Middle ears

Other

**PITUITARY** disrupted due to GSW.**SPINAL CORD** ☒**TOXICOLOGY SPECIMENS**

Blood vitreous

Liver bile

urine

**SECTIONS FOR HISTOPATHOLOGY**

none

**MICROBIOLOGY**

none

**DIAGRAMS****X-RAYS** 2**OTHER PROCEDURES****GROSS IMPRESSIONS**

Gunshot wound  
of head

Date

5/1/2010

Time

8:30

Deputy Medical Examiner





Department of Coroner, County of Los Angeles  
**FORENSIC SCIENCE LABORATORIES**  
Laboratory Analysis Summary Report



To: Dr. Carrillo  
Deputy Medical Examiner

☐ Pending Tox

The following results have been technically and administratively reviewed and are the opinions and interpretations of the Analyst:

Coroner Case Number: 2010-02964 Decedent: LOPEZ, PETER MICHAEL

<u>SPECIMEN</u>	<u>SERVICE</u>	<u>DRUG</u>	<u>LEVEL</u>	<u>UNITS</u>	<u>ANALYST</u>
Blood, Heart					
	Alcohol	Ethanol	Negative		M. Schuchardt
	Barbiturate	Barbiturates	ND		J. Lintemoot
	Bases	Basic Drugs	ND		S. DeQuintana
	Cocaine	Cocaine and Metabolites	ND		J. Lintemoot
	ELISA	Benzodiazepines	ND		J. Lintemoot
	ELISA	Lorazepam	ND		J. Lintemoot
	Fentanyl	Fentanyl	ND		J. Lintemoot
	Methamphetamine	Methamphetamine	ND		J. Lintemoot
	Opiates	Codeine	ND		J. Lintemoot
	Opiates	Morphine	ND		J. Lintemoot
	Phencyclidine	Phencyclidine	ND		J. Lintemoot

Legend:

		ND	Not Detected
g	Grams	ng/gm	Nanograms per Gram
g%	Gram Percent	ng/ml	Nanograms per Milliliter
Inc.	Inconclusive	QNS	Quantity Not Sufficient
mg	Milligrams	TNP	Test Not Performed
mg/dl	Milligram per Deciliter	ug	Micrograms
mg/l	Milligram per Liter	ug/g	Micrograms per Gram
		ug/ml	Microgram per Milliliter

Administratively reviewed by: Daniel T. Anderson, M.S., FTS-ABFT, D-ABC  
Supervising Criminalist II  
TOXICOLOGY



COUNTY OF LOS ANGELES

## CASE REPORT

DEPARTMENT OF CORONER

<b>1</b>	APPARENT MODE <b>SUICIDE</b>	CASE NO <b>2010-02964</b>
	SPECIAL CIRCUMSTANCES <b>Celebrity, Gunshot Wound, Media Interest</b>	CRYPT <b>204</b>

LAST, FIRST MIDDLE <b>LOPEZ, PETER MICHAEL</b>	AKA	#
---	-----	---

ADDRESS <b>15930 WOODVALE ROAD</b>	CITY <b>ENCINO</b>	STATE <b>CA</b>	ZIP <b>91436</b>
---------------------------------------	-----------------------	--------------------	---------------------

SEX <b>MALE</b>	RACE APPEARS <b>HISPANIC/LATINO AMERICAN</b>	DOB <b>6/7/1949</b>	AGE <b>60</b>	HGT <b>71 in.</b>	WGT <b>174 lbs.</b>	EYES <b>BROWN</b>	HAIR <b>BALD</b>	TEETH <b>ALL NATURAL TEETH</b>	FACIAL HAIR <b>NONE</b>	ID VIEW <b>Yes</b>	CONDITION <b>HEAD TRAUMA</b>
--------------------	--	------------------------	------------------	----------------------	------------------------	----------------------	---------------------	---------------------------------------	----------------------------	-----------------------	---------------------------------

MARK TYPE	MARK LOCATION	MARK DESCRIPTION
		<b>NONE NOTED</b>

LA #	MAIN #	CII #	FBI #	MILITARY #	POB

IDENTIFIED BY NAME (PRINT)	RELATIONSHIP	PHONE	DATE	TIME
<b>INV. TRINI GODOY</b>	<b>NONE</b>	<b>(818) 364-3323</b>	<b>4/30/2010</b>	

PLACE OF DEATH / PLACE FOUND <b>RESIDENCE</b>	ADDRESS OR LOCATION <b>15930 WOODVALE ROAD</b>	CITY <b>ENCINO</b>	ZIP <b>91436</b>
--	---	-----------------------	---------------------

PLACE OF INJURY <b>RESIDENCE</b>	AT WORK <b>No</b>	DATE <b>4/30/2010</b>	TIME <b>11:22</b>	LOCATION OR ADDRESS <b>15930 WOODVALE ROAD, ENCINO, CA</b>	ZIP <b>91436</b>
-------------------------------------	----------------------	--------------------------	----------------------	---	---------------------

DOD <b>4/30/2010</b>	TIME <b>11:40</b>	FOUND OR PRONOUNCED BY <b>LAFD RA #83</b>
-------------------------	----------------------	--

OTHER AGENCY INV. OFFICER <b>LAPD WEST VALLEY - OFFICER MIKEL #36825</b>	PHONE <b>(818) 374-7611</b>	REPORT NO. <b>10-1748</b>	NOTIFIED BY	NO
---	--------------------------------	------------------------------	-------------	----

TRANSPORTED BY <b>LUCIA MONTOYA</b>	TO <b>LOS ANGELES FSC</b>	DATE <b>4/30/2010</b>	TIME <b>16:11</b>
--	------------------------------	--------------------------	----------------------


FINGERPRINTS? <b>Yes</b>	CLOTHING <b>Yes</b>	PA RPT <b>No</b>	MORTUARY
-----------------------------	------------------------	---------------------	----------

MED. EV. <b>Yes</b>	INVEST. PHOTO # <b>10</b>	SEAL TYPE <b>NOT SEALED</b>	HOSP RPT <b>No</b>
------------------------	------------------------------	--------------------------------	-----------------------

PHYS. EV. <b>Yes</b>	EVIDENCE LOG <b>Yes</b>	PROPERTY? <b>Yes</b>	HOSP CHART <b>No</b>
-------------------------	----------------------------	-------------------------	-------------------------

SUICIDE NOTE <b>Yes</b>	GSR NO <b>C4177</b>	RCPT. NO. <b>243084</b>	PF NO.
----------------------------	------------------------	----------------------------	--------

SYNOPSIS  
ON 04/30/2010, AT APPROXIMATELY 1122 HOURS, A GUNSHOT WAS HEARD. OCCUPANTS IN THE HOME WENT TO INVESTIGATE. THE DECEDENT WAS DISCOVERED WITH AN APPARENT SELF INFLICTED GUNSHOT WOUND TO THE HEAD BY THE HOUSEKEEPER. 9-1-1 WAS CALLED. LAFD RESPONDED AND DETERMINED DEATH AT 1140 HOURS. THE DECEDENT HAS NO KNOWN MEDICAL HISTORY. HE HAS NO HISTORY OF PRIOR ATTEMPTS OR IDEATIONS. A NOTE WAS PRESENT. NO FOUL PLAY WAS INDICATED.

TRINI GODOY 467561		INVESTIGATOR	DATE <b>4/30/2010</b>	REVIEWED BY	DATE
			TIME <b>21:25</b>		TIME

FORM #3 NARRATIVE TO FOLLOW? ☒





## County of Los Angeles, Department of Coroner Investigator's Narrative



Case Number: 2010-02964

Decedent: LOPEZ, PETER MICHAEL

### Information Sources:

- 1) LAPD/West Valley Division Officer Mikel #36825 (818) 374-7611
- 2) LAFD/Emergency Medical Services Report #633555
- 3) Los Angeles County Coroner Assistant Chief Winter (323) 343-0714
- 4) On scene investigation

### Investigation:

On 04/30/2010, at 1227 hours, officer Mikel reported a possible suicide death to the Los Angeles County Department of Coroner-reporting desk. Lt. Elias assigned this case to me for investigation at 1325 hours. I responded from a previous field call in Encino. I arrived on scene at 1337 hours and concluded my scene investigation at 1536 hours. L.A. County Coroner Assistant Chief Winter also responded to the scene. F.A. Montoya transported the decedent to FSC.

### Location:

Residence rear yard 15930 Woodvale Road Encino, CA 91436

### Informant/Witness Statements:

According to Officer Mikel, on 04/30/2010, at about 1122 hours, a gunshot was heard by the occupants of the home. Several went out to the rear yard to investigate. The housekeeper Delmy Henriquez (818) 402-2793 went up the wooden stairs and discovered the decedent unresponsive with a gunshot wound at 1127 hours. She yelled to the other to call 9-1-1. 9-1-1 was called. LAFD RA #83, AE #099, and EMS #10 responded to the location. Firefighter/paramedic Stewart #59320 determined death at 1140 hours without medical intervention. The decedent has no known history of suicide attempts or ideations.

According to LAFD/Emergency Medical Services Report, the time of alarm was 1128 hours. The first unit on scene arrived at 1135 hours. They found the male supine with a handgun in his right hand and a wound to the right temple.

Assistant Chief Winter provided the following information to me after he was able to meet with the decedents next of kin. The decedent has no known medical history although he had some flu-like symptoms for the past several weeks. He has not been having any financial or relationship difficulties.

### Scene Description:

The scene is the rear yard located at the above listed address. The decedent was found up a hillside located at the south end of the yard. Wooden stairs lead up the hillside to a hilltop viewing deck. The decedent was found just east of the deck and south of the wooden stairs. He was lying supine with his head to the west and feet to the east, a chain link fence was to the south of the decedent. The weapon had been moved prior to my arrival at the request of LAFD, but was reportedly found in the decedents right hand. The gun is a Colt Cobra .38 special revolver bearing serial number 95848M. It was loaded with 1 expended casing. The expended casing was marked Smith & Wesson while the live rounds were marked "Spears" and all were .38 caliber. The weapon did have some blood on the muzzle. A note had been located in a pool house in the rear yard by Garnetta Burns (818) 448-0191. Ms. Burns had seen the decedent in the pool house writing on the same tablet prior to the shot being heard. It states the decedent loved his family.





County of Los Angeles, Department of Coroner  
Investigator's Narrative



Case Number: 2010-02964

Decedent: LOPEZ, PETER MICHAEL

**Evidence:**

On 04/30/2010, at 1442 hours, I collected GSR kit #C4177 while at the scene.

**Body Examination:**

The decedent appears to be a well nourished adult Hispanic male. Upon my arrival, he was found in a supine position in the dirt adjacent to some wooden stairs. He was wearing a black jacket, gray sweatshirt, white shirt, blue pants, black underwear, white socks, gray/white shoes, and a black baseball cap. The ambient temperature was 75 degrees at 1508 hours. The body temperature was 98 degrees at 1513 hours. Rigor mortis was noted at 1 throughout. Lividity blanched with light pressure and appears consistent with a supine position. A large gunshot wound was noted to the temple. The skull has palpable fractures.

**Identification:**

On 04/30/2010, I visually identified the decedent while at the scene via CA drivers license #R0858093 as Peter Michael Lopez.

**Next of Kin Notification:**


On 04/30/2010, ~~Trini Godoy~~ was present at the scene and notified of the death of her husband.

**Tissue Donation:**

The next of kin was too distraught to be approached regarding donation.

**Autopsy Notification:**

Not requested by law enforcement.

  
TRINI GODOY 467561

\_\_\_\_\_  
BRIAN ELIAS

04/30/2010

Date of Report



**3A**

CASE # 2010-02964  
DECEDENT'S NAME: LOPEZ, PETER MICHAËL  
DOD: 4/30/2010  
INCOMING MODE:

Page 1 of 1

Drug Name	Rx Number	Date of Issue	Number Issued	Number Remaining	Form	Dosage	Rx Directions	Physician	Pharmacy Phone/ Comments
LORAZEPAM	05670034228	4/14/2010	20	19	TABLET	0.5MG	1 TAB AT BEDTIME	DR. GOLD	RITE AID (818)783-2449 DECEDENT'S PRESCRIPTION
Paraphernalia Description									
Investigator: TRINI GODOY (467561)									Date: 4/30/2010



**6**WAS ORIGINAL SCENE DISTURBED BY OTHERS? ☒ YES ☐ NO ☐ IF YES, NOTE CHANGES IN NARRATIVE FORM #3.DATE 04/30/2010AMBIENT #1 75 °FAMBIENT #2 / °FWATER / °FTIME 1508TIME /TIME /TIME 1513TIME -

2010-02964

LOPEZ, PETER

DOD: 04/30/2010 1140

LAPD/West Valley

SUI/GSW

THERMOMETER # 01-32LIVER TEMPERATURE #1 98 °FLIVER TEMPERATURE #2 - °FDATE & TIME FOUND 04/30/2010 1127 LAST KNOWN ALIVE 04/30/2010 1120APPROX. AGE 60 SEX M EST. HEIGHT 71 EST. WEIGHT 174 CLOTHED? YES ☒ NO ☐ IF YES, DESCRIBE:BLACK JACKET, GRAY SWEATSHIRT, WHITE SHIRT, BLUE PANTS, BLACK UNDERWEAR, WHITE SOCKS, GRAY/WHITE SHOES, AND A BLACK BASEBALL HAT.

DESCRIPTION AS TO WHERE REMAINS FOUND AND CONTACT MATERIAL TO BODY:

SUPINE IN DIRT ADJACENT TO WOODEN STEPS.SCENE TEMPERATURE REGULATED? YES ☐ NO ☒ IF YES, THERMOSTAT SET AT \_\_\_\_\_ DEGREES F.LIVOR MORTIS: TIME OBSERVED 1427RIGOR MORTIS: TIME OBSERVED 1427

NECK FLEXION:

ANTERIOR /POSTERIOR /RT. LATERAL /LT. LATERAL /JAW / HIP /SHOULDER / KNEE /ELBOW / ANKLE /WRIST /

SCALE

0 = ABSENT/NEGATIVE

1 +

2 +

3 +

4 = EXTREME DEGREE

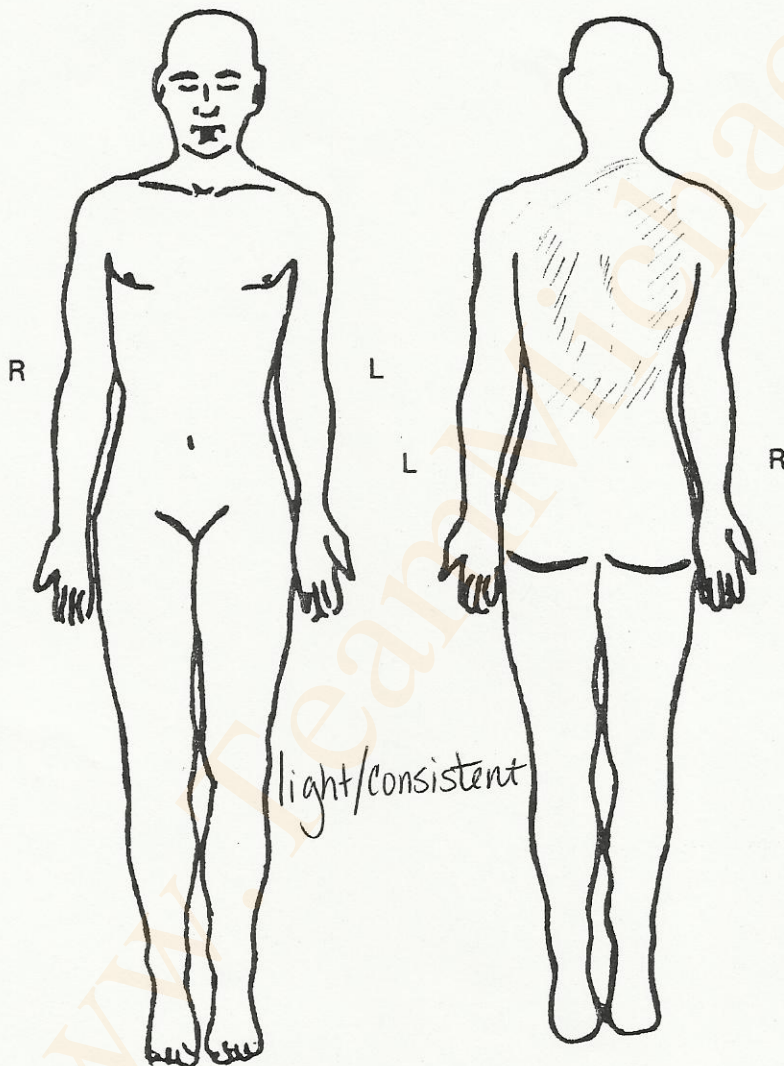
USE SCALE TO DESCRIBE INTENSITY OF RIGOR MORTIS.

SHADE DIAGRAMS TO ILLUSTRATE THE LOCATION OF LIVOR MORTIS.

DESCRIBE INTENSITY OF COLORATION AND WHETHER LIVOR MORTIS IS PERMANENT OR BLANCHES UNDER PRESSURE.

Cor. Godoy #467561  
CORONER'S INVESTIGATOR

REVIEWED BY:





82

- ☐ Accident  
☐ Homicide  
☒ Suicide  
☐ Questionable Accident/Homicide  
☐ Questionable Accident/Suicide  
☐ Questionable Suicide/Homicide  
☐ Investigator Requests Rush

Kit #

C4177

2010-02964  
LOPEZ, PETER  
DOB: 04/30/2010 1140  
LAPD/West Valley  
SUI/GSW  
☒ Male ☐ Female

INFORMATION ABOUT DECEDENT/SHOOTING

☒ Right Handed ☐ Left Handed ☐ Unknown

Occupation ATTORNEY ☐ Unknown

Activity Prior to Shooting UNKNOWN

Have the decedent's hands been touched by anyone prior to taking the GSR sample? ☐ Yes ☐ No ☒ Unknown

If yes, by whom? ☐ Paramedics ☐ Family ☐ Police ☐ Hospital Personnel  
☐ Other

Was the weapon found in the decedent's hand? ☐ Yes ☐ No ☒ Unknown - Moved prior arrival

If yes, which one? ☐ Right ☐ Left

If no, describe weapon's location in relationship to decedent

Shooting Occurred: ☐ Indoors ☒ Outdoors ☐ Unknown

Location of Body: ☐ Indoors ☒ Outdoors ☐ Automobile ☐ Hospital  
Other

Number of Shots Fired: 1

Date 04/30/2010 and Time 1122 of Shooting

Date 04/30/2010 and Time 1442 GSR samples were taken.

GSR evidence collected ☒ At Scene ☐ At FSC ☐ At Hospital  
☐ Other By:

Body transported to FSC via ☒ Coroner ☐ Contractor

FIREARM

☒ Revolver ☐ Semi-automatic/automatic ☐ Rifle ☐ Shotgun

☐ Other

Make/Model COLT COBRA Caliber .38 SPECIAL

AMMUNITION

Brand of Ammunition SMITH & WESSON (CASING) Caliber of Ammunition .38  
LIVE (SPEARS)

Bullet Configuration: ☐ Round Nose ☐ Hollow Point ☐ Wad Cutter ☐ Pointed

Other

Bullet Surface: ☐ Jacketed ☐ Semi-jacketed ☐ Bare Lead ☐ Plated

Comments:

*Lin Godoy*  
Investigator 46756

04/30/2010  
Date

Do not write below this line

RESULTS:

White: Medical file  
Pink: Laboratory Copy  
Yellow: Laboratory Copy